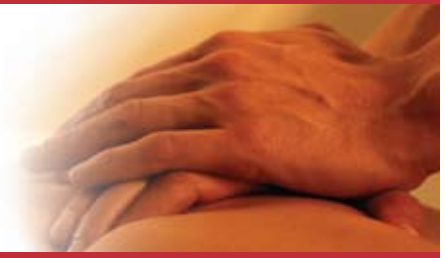

Hands On

Practical advice on management of rheumatic disease



pGALS – A SCREENING EXAMINATION OF THE MUSCULO-SKELETAL SYSTEM IN SCHOOL-AGED CHILDREN

Helen E Foster, MD, MBBS(Hons), FRCP, FRCPC, CertMedEd, Professor in Paediatric Rheumatology
Sharmila Jandial, MBChB, MRCPCH, CertMedEd, **arc** Educational Research Fellow

Musculoskeletal Research Group, Newcastle University, Newcastle upon Tyne

June 2008 No 15

Why do primary care doctors need to know about musculoskeletal assessment in children?

Children with musculoskeletal (MSK) problems are common and often present initially to primary care where GPs have an important role as 'gatekeepers' to secondary care and specialist services. The majority of causes of MSK presentations in childhood are benign, self-limiting and often trauma-related; referral is not always necessary, and in many instances reassurance alone may suffice. However, MSK symptoms can be presenting features of potentially life-threatening conditions such as malignancy, sepsis, vasculitis and non-accidental injury, and furthermore are commonly associated features of many chronic paediatric conditions such as inflammatory bowel disease, cystic fibrosis, arthritis and psoriasis. Clinical assessment skills (history-taking and physical examination), knowledge of normal development, and clinical presentations at different ages, along with knowledge of indicators to warrant referral, are important and facilitate appropriate decision-making in the primary care setting. This article focuses on pGALS (paediatric Gait, Arms, Legs, Spine), which is a simple screening approach to MSK examination in school-aged children and may be successfully performed in younger ambulant children – the approach to the examination of the toddler and baby requires a different approach and is not described here.

How is musculoskeletal assessment of children different to that of adults?

It is stating the obvious that children are 'not small adults' in many ways, and here we focus on MSK history-taking

and physical examination. The history is often given by the parent or carer, may be based on observations and interpretation of events made by others (such as teachers), and may be rather vague with non-specific complaints such as 'My child is limping' or 'My child is not walking quite right'. Young children may have difficulty in localising or describing pain in terms that adults may understand. It is not unusual for young children to deny having pain when asked directly, and instead present with changes in behaviour (e.g. irritability or poor sleeping), decreasing ability or interest in activities and hand skills (e.g. handwriting), or regression of motor milestones. Some children are shy or frightened and reluctant to engage in the consultation.

Practical Tip – when inflammatory joint disease is suspected

- The lack of reported pain does not exclude arthritis
- There is a need to probe for symptoms such as
 - gelling (e.g. stiffness after long car rides)
 - altered function (e.g. play, handwriting skills, regression of motor milestones)
 - deterioration in behaviour (irritability, poor sleeping)
- There is a need to examine all joints as joint involvement is often 'asymptomatic'

It is important to probe in the history when there are indicators of potential inflammatory MSK disease. A delay in major motor milestones warrants MSK assessment as well as a global neuro-developmental approach. However, in acquired MSK disease such as juvenile idiopathic arthritis (JIA) a history of *regression* of achieved milestones is often more significant – e.g. the child who was happy to walk unaided but has recently been reluctant to walk or is now unable to dress himself without help. In adults the cardinal features of inflammatory arthritis are pain, stiffness, swelling and reduced function. However, in children these features may

be difficult to elucidate. Joint swelling, limping and reduced mobility, rather than pain, are the most common presenting features of JIA.¹ The lack of reported pain does not exclude arthritis – the child is undoubtedly in discomfort but, for the reasons described, may not verbalise this as pain. Swelling is always significant but can be subtle and easily overlooked, especially if the changes are symmetrical, and relies on the examiner being confident in their MSK examination skills and having an appreciation of what is ‘normal’ and ‘abnormal’ (see below). Rather than describing stiffness, the parents may notice the child is reluctant to weight-bear or limps in the mornings or ‘gels’ after periods of immobility (e.g. after long car rides or sitting in a classroom). Systemic upset and the presence of bone rather than joint pain may be features of MSK disease and are ‘red flags’ that warrant urgent referral. More indolent presentations of MSK disease can also impact on growth (either localised or generalised) and it is important to assess height and weight and review growth charts as necessary.

RED FLAGS (Raise concern about infection, malignancy or non-accidental injury)
<ul style="list-style-type: none"> • Fever, malaise, systemic upset (reduced appetite, weight loss, sweats) • Bone or joint pain with fever • Refractory or unremitting pain, persistent night-waking • Incongruence between history and presentation (such as the pattern of the physical findings and a previous history of neglect)

What is pGALS?

Paediatric GALS (pGALS) is a simple evidence-based approach to an MSK screening assessment in school-aged children, and is based on the adult GALS (Gait, Arms, Legs, Spine) screen.² The adult GALS screen is commonly taught to medical students, and emerging evidence shows an improvement in doctors’ confidence and performance in adult MSK assessment. Educational resources to support learning of GALS are available.³ pGALS is the only paediatric MSK screening examination to be validated, and was originally tested in school-aged children. pGALS has been demonstrated to have excellent sensitivity to detect abnormality (i.e. with few false negatives), incorporates simple manoeuvres often used in clinical practice, and is quick to do, taking an average of 2 minutes to perform.⁴ Furthermore, when performed by medical students and general practitioners pGALS has been shown to have high sensitivity and is easy to do, with excellent acceptability by children and their parents (papers in preparation). Younger children can often perform the screening manoeuvres quite easily, although validation of pGALS in the pre-school age group has yet to be demonstrated.

When should pGALS be performed?

MSK presentations are a common feature of many chronic diseases of childhood and not just arthritis. An MSK examination is one of the ‘core’ systems along with cardiovascu-

lar, respiratory, gastrointestinal, neurological, skin and eyes, and, given the broad spectrum of MSK presentations in children, a low threshold for performing pGALS is suggested and of particular importance in certain clinical scenarios.

Practical Tip – when to perform pGALS in the assessment

- Child with muscle, joint or bone pain
- Unwell child with pyrexia
- Child with limp
- Delay or regression of motor milestones
- The ‘clumsy’ child in the absence of neurological disease
- Child with chronic disease and known association with MSK presentations

How does pGALS differ from adult GALS?

The sequence of pGALS is essentially the same as adult GALS with additional manoeuvres to screen the foot and ankle (*walk on heels and then on tiptoes*), wrists (*palms together and then hands back to back*) and temporomandibular joints (*open mouth and insert three of the child’s own fingers*), and with amendments at screening the elbow (*reach up and touch the sky*) and neck (*look at the ceiling*). These additional manoeuvres were included because when adult GALS was originally tested in school-aged children⁴ it missed significant abnormalities at these sites.

How to distinguish normal from abnormal in the musculoskeletal examination

Key to distinguishing normal from abnormal are knowledge of ranges of movement, looking for asymmetry and careful examination for subtle changes. In addition, it is important that GPs are aware of normal variants in gait, leg alignment and normal motor milestones (Tables 1,2) as these are a common cause of parental concern, especially in the pre-school child, and often anxieties can be allayed with explanation and reassurance. There is considerable variation in the way normal gait patterns develop; these may be familial (e.g. ‘bottom-shufflers’ often walk later) and subject to racial variation (e.g. African black children tend to walk sooner and Asian children later than average).

Joint abnormalities can be subtle or difficult to appreciate in the young (such as ‘chubby’ ankles, fingers, wrists and knees). Looking for asymmetrical changes is helpful although it can be falsely reassuring in the presence of symmetrical joint involvement. Muscle wasting, such as of the quadriceps or calf muscles, indicates chronicity of joint disease and should alert the examiner to knee or ankle involvement respectively. Swelling of the ankle is often best judged from behind the child. Ranges of joint movement should be symmetrical and an appreciation of the ‘normal’ range of movement in childhood can be gained with increased clinical experience. Hypermobility may be generalised or limited to peripheral joints such as hands

Toe-walking	Habitual toe-walking is common in young children up to 3 years
In-toeing	Can be due to: <ul style="list-style-type: none"> • persistent femoral anteversion (characterised by child walking with patellae and feet pointing inwards; common between ages 3–8 years) • internal tibial torsion (characterised by child walking with patellae facing forward and toes pointing inwards; common from onset of walking to 3 years) • metatarsus adductus (characterised by a flexible ‘C-shaped’ lateral border of the foot; most resolve by 6 years)
Bow legs (genu varus)	Common from birth to the early toddler, often with out-toeing (maximal at approx. 1 year); most resolve by 18 months
Knock knees (genu valgus)	Common and often associated with in-toeing (maximal at approx. 4 years); most resolve by 7 years
Flat feet	Most children have flexible flat feet with normal arches on tiptoeing; most resolve by 6 years
Crooked toes	Most resolve with weight-bearing (assuming shoes and socks fit comfortably)

Sit without support	6–8 months
Creep on hands and knees	9–11 months
Cruise when holding on to furniture and standing upright, or bottom shuffle	11–12 months
Walk independently	12–14 months
Climb up stairs on hands and knees	approx. 15 months
Run stiffly	approx. 16 months
Walk down steps (non-reciprocal)	20–24 months
Walk up steps, alternate feet	3 years
Hop on one foot, broad jump	4 years
Skip with alternate feet	5 years
Balance on one foot 20 seconds	6–7 years

and feet, and, generally speaking, younger female children and those of non-Caucasian origin are more flexible. Benign hypermobility is suggested by symmetrical hyperextension at the fingers, elbows and knees and by flat pronated feet, with normal arches on tiptoe.⁵

Practical Tip – normal variants: indications for referral

- Persistent changes (beyond the expected age ranges)
- Progressive or asymmetrical changes
- Short stature or dysmorphic features
- Painful changes with functional limitation
- Regression or delayed motor milestones
- Abnormal joint examination elsewhere
- Suggestion of neurological disease or developmental delay

Children with hypermobility may present with mechanical aches and pains after activity or as ‘clumsy’ children, prone to falls. It is important to consider ‘non-benign’ causes of hypermobility such as Marfan’s syndrome (which may be suggested by tall habitus with long thin fingers, and high-arched palate), and Ehlers–Danlos syndrome (which may be suggested by easy bruising and skin elasticity, with poor healing after minor trauma). Non-benign hypermobility is genetically acquired and probing into the family history may be revealing (e.g. cardiac deaths in Marfan’s syndrome).

The absence of normal arches on tiptoe suggests a non-mobile flat foot and warrants investigation (e.g. to exclude tarsal coalition) and high fixed arches and persistent toe-walking may suggest neurological disease. Conversely, lack of joint mobility, especially if asymmetrical, is always significant. Increased symmetrical calf muscle bulk associates with types of muscular dystrophy, and proximal myopathies may be suggested by delayed milestones such as walking (later than 18 months) or inability to jump (in the school-aged child).

What to do if the pGALS screen is abnormal

pGALS has been shown to have high sensitivity to detect significant abnormalities. Following the screening examination, the observer is directed to a more detailed examination of the relevant area, based on the ‘look, feel, move’ principle as in the adult Regional Examination of the Musculoskeletal System (called REMS).³ To date a validated regional MSK examination for children does not exist, but an evidence- and consensus-based approach to a children’s regional examination (to be called pREMS) is currently being developed by our research team; this project is funded by **arc** and further educational resources are to follow.


The components of the pGALS musculoskeletal screen

The pGALS screen⁶ (see pp 4–6) includes three questions relating to pain and function. However, a negative response to these three questions in the context of a potential MSK problem does *not* exclude significant MSK disease, and






The pGALS musculoskeletal screen

Screening questions







- Do you (or does your child) have any pain or stiffness in your (their) joints, muscles or back?
- Do you (or does your child) have any difficulty getting yourself (him/herself) dressed without any help?
- Do you (or does your child) have any problem going up and down stairs?

FIGURE	SCREENING MANOEUVRES (Note the manoeuvres in bold are additional to those in adult GALS ²)	WHAT IS BEING ASSESSED?
	<p>Observe the child standing (from front, back and sides)</p>	<ul style="list-style-type: none"> • Posture and habitus • Skin rashes – e.g. psoriasis • Deformity – e.g. leg length inequality, leg alignment (valgus, varus at the knee or ankle), scoliosis, joint swelling, muscle wasting, flat feet
	<p>Observe the child walking and ‘Walk on your heels’ and ‘Walk on your tiptoes’</p>	<ul style="list-style-type: none"> • Ankles, subtalar, midtarsal and small joints of feet and toes • Foot posture (note if presence of normal longitudinal arches of feet when on tiptoes)
	<p>‘Hold your hands out straight in front of you’</p>	<ul style="list-style-type: none"> • Forward flexion of shoulders • Elbow extension • Wrist extension • Extension of small joints of fingers
	<p>‘Turn your hands over and make a fist’</p>	<ul style="list-style-type: none"> • Wrist supination • Elbow supination • Flexion of small joints of fingers
	<p>‘Pinch your index finger and thumb together’</p>	<ul style="list-style-type: none"> • Manual dexterity • Coordination of small joints of index finger and thumb and functional key grip

(continued)

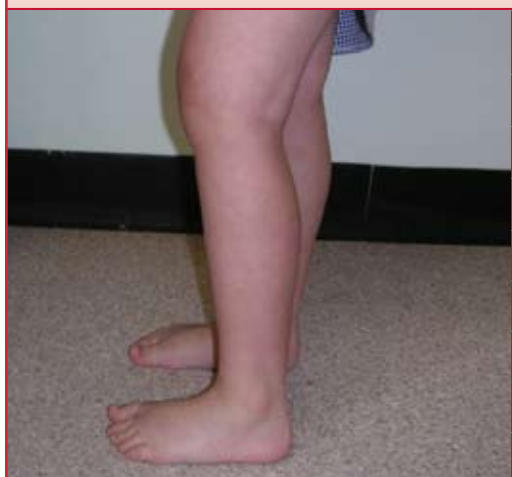FIGURE	SCREENING MANOEUVRES	WHAT IS BEING ASSESSED?
	<p>‘Touch the tips of your fingers’</p>	<ul style="list-style-type: none"> • Manual dexterity • Coordination of small joints of fingers and thumbs
	<p>Squeeze the metacarpophalangeal joints for tenderness</p>	<ul style="list-style-type: none"> • Metacarpophalangeal joints
	<p>‘Put your hands together palm to palm’ and ‘Put your hands together back to back’</p>	<ul style="list-style-type: none"> • Extension of small joints of fingers • Wrist extension • Elbow flexion
	<p>‘Reach up, “touch the sky” and ‘Look at the ceiling’</p>	<ul style="list-style-type: none"> • Elbow extension • Wrist extension • Shoulder abduction • Neck extension
	<p>‘Put your hands behind your neck’</p>	<ul style="list-style-type: none"> • Shoulder abduction • External rotation of shoulders • Elbow flexion

(continued)

FIGURE	SCREENING MANOEUVRES	WHAT IS BEING ASSESSED?
	<p>'Try and touch your shoulder with your ear'</p>	<ul style="list-style-type: none"> • Cervical spine lateral flexion
	<p>'Open wide and put three (child's own) fingers in your mouth'</p>	<ul style="list-style-type: none"> • Temporomandibular joints (and check for deviation of jaw movement)
	<p>Feel for effusion at the knee (patella tap, or cross-fluctuation)</p>	<ul style="list-style-type: none"> • Knee effusion (small effusion may be missed by patella tap alone)
	<p>Active movement of knees (flexion and extension) and feel for crepitus</p>	<ul style="list-style-type: none"> • Knee flexion • Knee extension
	<p>Passive movement of hip (knee flexed to 90°, and internal rotation of hip)</p>	<ul style="list-style-type: none"> • Hip flexion and internal rotation
	<p>'Bend forwards and touch your toes?'</p>	<ul style="list-style-type: none"> • Forward flexion of thoraco-lumbar spine (and check for scoliosis)

Documentation of the pGALS screen

Documentation of the pGALS screening assessment is important and a simple pro forma is proposed with the following example – a child with a swollen left knee with limited flexion of the knee and antalgic gait.



pGALS screening questions		
Any pain?	<i>Left knee</i>	
Problems with dressing?	<i>No difficulty</i>	
Problems with walking?	<i>Some difficulty on walking</i>	
	Appearance	Movement
Gait		X
Arms	✓	✓
Legs	X	X
Spine	✓	✓

therefore at a minimum pGALS should be performed. In children, it is not uncommon to find joint involvement that has not been mentioned as part of the presenting complaint; it is therefore essential to perform all parts of the pGALS screen and check for verbal and non-verbal clues of joint discomfort (such as facial expression, withdrawal of limb, or refusal to be examined further).

Observation with the child standing should be done from the front, behind the child and from the side. Scoliosis may be suggested by unequal shoulder height or asymmetrical skin creases on the trunk, and may be more obvious on forward flexion. From the front and back, leg alignment problems such as valgus and varus deformities at the knee can be observed; leg-length inequality may be more obvious from the side and suggested by a flexed posture at the knee, and, if found, then careful observation of the spine is important to exclude a secondary scoliosis. For specific manoeuvres, the child can copy the various screening manoeuvres as they are performed by the examiner. Children often find this fun and this can help with establishing rapport. It is important to keep observing closely as children may only cooperate briefly! The examination of the upper limbs and neck is optimal with the child sitting on an examination couch or on a parent's knee, facing the examiner. The child should then lie supine to allow the legs to be examined and then stand again for spine assessment.

Practical Tip – while performing the pGALS screening examination

- Get the child to copy you doing the manoeuvres
- Look for verbal and non-verbal clues of discomfort (e.g. facial expression, withdrawal)
- Do the full screen as the extent of joint involvement may not be obvious from the history
- Look for asymmetry (e.g. muscle bulk, joint swelling, range of joint movement)
- Consider clinical patterns (e.g. non-benign hypermobility and Marfanoid habitus or skin elasticity) and association of leg-length discrepancy and scoliosis)

Summary

The pGALS examination is a simple MSK screen that should be performed as part of systems assessment of children. Improved performance of MSK clinical skills and knowledge of normal variants in childhood, common MSK conditions and their mode of presentation, along with knowledge of red flags to warrant concern, will facilitate diagnosis, management and appropriate referral.

Further information and reading

A full demonstration of the pGALS screen is available from the Arthritis Research Campaign (**arc**) as a free resource as a DVD and soon will be available as a web-based resource: www.arc.org.uk/arthritis/emedial.asp. A video-clip of the screening manoeuvres can also be accessed via the web version of this report: www.arc.org.uk/arthritis/medpubs/6535/6535.asp.

Jandial S, Foster HE. Examination of the musculoskeletal system in children: a simple approach. *Paediatr Child Health* 2008;18(2):47-55.

Szer I, Kimura Y, Malleon P, Southwood T (ed). *Arthritis in adolescents and children (juvenile idiopathic arthritis)*. Oxford University Press; 2006.

References

1. McGhee JL, Burks FN, Sheckels JL, Jarvis JN. Identifying children with chronic arthritis based on chief complaints: absence of predictive value for musculoskeletal pain as an indicator of rheumatic disease in children. *Pediatrics* 2002;110(2 Pt 1):354-9.
2. Doherty M, Dacre J, Dieppe P, Snaith M. The 'GALS' locomotor screen. *Ann Rheum Dis* 1992;51(10):1165-9.
3. Clinical assessment of the musculoskeletal system: a handbook for medical students (includes DVD 'Regional examination of the musculoskeletal system for students'). Arthritis Research Campaign; 2005. www.arc.org.uk/arthritis/medpubs/6321/6321.asp.
4. Foster HE, Kay LJ, Friswell M, Coady D, Myers A. Musculoskeletal screening examination (pGALS) for school-aged children based on the adult GALS screen. *Arthritis Rheum* 2006;55(5):709-16.
5. Oliver J. Hypermobility. Reports on the Rheumatic Diseases (Series 5), Hands On 7. Arthritis Research Campaign; 2005 Oct.
6. pGALS – Paediatric Gait, Arms, Legs, Spine. DVD. Arthritis Research Campaign; 2006. www.arc.org.uk/arthritis/emedial.asp.

COMMENT

Elsbeth M Wise, MA, MBBChir, MRCPGP, DRCOG
General Practitioner, Durham/former **arc** Education Fellow

This is an excellent report highlighting some important areas in paediatric musculoskeletal disorders: clinical skills and normal variants. Studies have shown that children with juvenile idiopathic arthritis are often delayed in accessing appropriate, specialist rheumatology services. This delay can occur both in primary care, where we may not recognise the symptoms early, and in secondary care, where children may be under the care of general paediatricians or orthopaedic surgeons for a while before being referred. It is therefore important that, as GPs, we know our local services and how best to access them.

Having used pGALS in primary care, I find the differences between GALS and pGALS useful to remember, i.e.

- *screen the foot and ankle (ask child to walk on heels and then tiptoes)*

- *check the wrists (ask child to form the prayer sign and then place their hands back to back)*
- *screen the elbow and neck (ask child to 'touch the sky' and then look at the ceiling)*
- *check the temporomandibular joints (ask child to open their mouth and insert 3 fingers).*

Normal variants are a common paediatric musculoskeletal presentation in primary care and can be a great source of concern for both parents and doctor. One way of remembering the variations in knee alignment is by 'the rule of 6': If the child is under 6 years old and there is less than 6 cm between the knees (if has bow legs) or 6 cm between the ankles (if has knock knees) then the problem is likely to be self-limiting. If unsure review and follow up the child.*

* Panayi G, Dickson DJ. Arthritis. In Clinical Practice Series. Edinburgh: Churchill Livingstone; 2004. pp 85-6.

This issue of 'Hands On' can be downloaded as html or a PDF file from the Arthritis Research Campaign website (www.arc.org.uk/about_arth/rdr5.htm) and follow the links).

*Hard copies of this and all other arc publications are obtainable via the on-line ordering system (www.arc.org.uk/orders), by email (arc@bradshawsdirect.co.uk), or from: **arc Trading Ltd, James Nicolson Link, Clifton Moor, York YO30 4XX.***